



## Review

## Neuroendocrine tumors of the gynecologic tract: A Society of Gynecologic Oncology (SGO) clinical document

Ginger J. Gardner<sup>a</sup>, Diane Reidy-Lagunes<sup>b</sup>, Paola A. Gehrig<sup>c,\*</sup><sup>a</sup> Department of Surgery, Memorial Sloan-Kettering Cancer Center, New York, NY, USA<sup>b</sup> Department of Medicine, Memorial Sloan-Kettering Cancer Center, New York, NY, USA<sup>c</sup> Division of Gynecologic Oncology, University of North Carolina at Chapel Hill, Chapel Hill, NC, USA

## ARTICLE INFO

## Article history:

Received 27 January 2011

## Keywords:

Neuroendocrine tumors  
Small cell carcinoma  
Carcinoid tumors

## ABSTRACT

**Objective.** Neuroendocrine tumors of the gynecologic tract are rare, and pose a significant clinical challenge because of the tumor heterogeneity and lack of standardized guidelines for treatment. This manuscript summarizes the available literature concerning these tumors in an effort to provide the clinician a framework from which to guide patient management.

**Methods.** MEDLINE was searched for all research articles published in English between January 1, 1966 and March 1, 2011 in which the studied population included women diagnosed with neuroendocrine tumors of the gynecologic tract. Although preference was given to prospective studies, studies were not limited by design or by numbers of subjects given the limited availability of reports.

**Results.** Most, but not all, neuroendocrine tumors of the gynecologic tract have an aggressive clinical course and those of the cervix histologically and clinically share similarities with small cell lung cancer. Cumulative data supports a multi-modality therapeutic strategy. A proposed management algorithm for neuroendocrine carcinomas of the cervix is outlined. For less frequent disease sites including the adnexa, uterus, vagina and vulva, as well as well differentiated carcinoid tumors, surgical resection is appropriate in selected cases. Etoposide/platinum based chemotherapy is used for neuroendocrine carcinomas but not for well differentiated carcinoid tumors. Well differentiated carcinoid and atypical carcinoid tumors should be managed similar to gastroenteropancreatic NETs (GEP-NETs).

**Conclusions.** Most neuroendocrine tumors of the gynecologic tract require a multi-modality therapeutic approach, determined by extent of disease and primary organ of involvement. Pathologic diagnosis is critical to guide therapy.

© 2011 Elsevier Inc. All rights reserved.

## Contents

SGO clinical document . . . . .	191
Introduction . . . . .	191
Methods . . . . .	191
Poorly differentiated neuroendocrine carcinomas (NECs) . . . . .	191
Small cell and large cell NECs of the cervix . . . . .	191
Diagnosis . . . . .	192
Management . . . . .	192
Early stage diseases . . . . .	192
Future research . . . . .	193
Small cell and large cell NECs of the ovary . . . . .	193
Small cell carcinoma of the uterus . . . . .	194
Small cell carcinoma of the vagina . . . . .	194
Small cell carcinoma of the vulva . . . . .	194
Well differentiated neuroendocrine tumors (NETs): Typical and atypical carcinoids. . . . .	194
Diagnosis and work-up . . . . .	194
Biochemical and cardiac monitoring . . . . .	194

\* Corresponding author at: Division of Gynecologic Oncology, CB # 7572, University of North Carolina at Chapel Hill, Chapel Hill, NC 27599-7572, USA. Fax: +1 919 966 2646.  
E-mail address: [pam68@med.unc.edu](mailto:pam68@med.unc.edu) (P.A. Gehrig).

Carcinoid of the ovary . . . . .	194
Insular carcinoid. . . . .	195
Trabecular carcinoid . . . . .	195
Mucinous carcinoid . . . . .	195
Management: role of tumor resection and localized treatment options . . . . .	195
Role of adjuvant therapy . . . . .	195
Advanced-stage and recurrent disease. . . . .	195
Future research . . . . .	195
Summary and recommendations . . . . .	196
Conflict of interest statement . . . . .	196
Acknowledgments . . . . .	196
References . . . . .	196

## SGO clinical document

The Society of Gynecologic Oncology (SGO) working through the Clinical Practice Committee (CPC) has developed a series of Clinical Documents designed in part to improve the overall quality of women's cancer care; reduce the use of unnecessary, ineffective or harmful interventions; as well as facilitate the optimal treatment of patients with a goal to maximize the therapeutic benefit, and minimize the risk of harm, at acceptable cost. SGO Clinical Documents remain strictly confidential and are not to be disclosed or disseminated by any participant in the process prior to the Document's publication. SGO Clinical Documents may have a direct impact on the practice of treating women with gynecologic malignancies. Clinical Documents are intended to be educational devices that provide information that may assist healthcare providers in caring for patients. This Clinical Document is not a rule and should not be construed as establishing a legal standard of care or as encouraging, advocating, requiring, or discouraging any particular treatment. Clinical Documents are not intended to supplant the judgment of the health care provider with respect to particular patients or special clinical situations. Clinical decisions in any particular case involve a complex analysis of the patient's condition and available courses of action with the ultimate determination to be made by the health care provider in light of each individual patient's circumstances. Therefore, clinical considerations may lead a healthcare provider to appropriately take a course of action that varies from this Document. This Clinical Document has met SGO's criteria of an Expert Clinical Opinion.

## Introduction

Neuroendocrine tumors consist of a spectrum of malignancies that arise from the diffuse neuroendocrine cell system. Prognosis is dependent on histologic subtype and site of origin. The family of well differentiated neoplasms (i.e. carcinoid and atypical carcinoid) is morphologically and clinically distinct from high-grade neuroendocrine carcinoma (i.e., small cell and large cell). This latter entity is closely related to pulmonary small-cell carcinoma, is highly aggressive, and is generally managed with a multimodality approach including platinum-based chemotherapy [1]. Well and poorly differentiated neuroendocrine tumors are grouped together only because of generic neuroendocrine marker expression (i.e. expression of the markers synaptophysin and chromogranin detected by immunohistochemistry). The biology and clinical outcome of poorly differentiated neuroendocrine carcinomas, however, are vastly different from the well differentiated neuroendocrine tumors. In fact, recent investigations at Memorial Sloan Kettering suggest that the poorly differentiated neuroendocrine carcinoma likely possesses a non-neuroendocrine cell lineage and is more closely related to a de novo carcinoma (Tang, L unpublished data).

In recent decades, there has been an increased reported incidence of neuroendocrine tumors, which may reflect improvements in standardized classification criteria, and increased diagnostic recogni-

tion [2]. Neuroendocrine tumors primary to the gynecologic tract are still considered to be uncommon, with limited prospective data from which to guide decisions. The goal of this manuscript is to provide a comprehensive review on gynecologic neuroendocrine tumors, and a platform from which to evaluate the available treatment options for these challenging cases.

## Methods

In 2007, at the 38th Annual Meeting on Women's Cancer, sponsored by the SGO, a subcommittee of the CPC was formed to begin development of clinical papers for subject areas where consensus was perceived as lacking. A MEDLINE search of English literature published between January 1966 and March 2011 was performed. All publications with the keywords "cervix", "ovary", "uterus", and "vagina" were combined and then searched for the keyword "neuroendocrine, small cell, carcinoid" in order to develop a comprehensive list of literature. Additional publications were identified by survey of reference lists within identified publications, and related articles pertaining to the management of small cell lung cancer.

While developing this document, the merit of creating inclusion and exclusion criteria based upon subject numbers within each study was considered. As with other reviews on less common gynecologic malignancies approved by the CPC, the lack of data in the form of large trials was determined to be a strong rationale for inclusion of all publications, including those reporting small pools of patients. Thus, all peer reviewed original report publications containing the appropriate subjects were considered.

## Poorly differentiated neuroendocrine carcinomas (NECs)

### *Small cell and large cell NECs of the cervix*

In 1997, a workshop sponsored by the College of American Pathologists and the NCI proposed standardized terminology for neuroendocrine tumors of the uterine cervix [3]. The nomenclature was created as a parallel to that used for pulmonary endocrine tumors, and four categories were identified: Small cell carcinoma, large cell neuroendocrine carcinomas, typical carcinoid tumors, and atypical carcinoid tumors. Each of the four histologic categories can be associated with an in situ or invasive squamous cell carcinoma or adenocarcinoma of the cervix. Unless the neuroendocrine component is present only as isolated tumor cells, the neuroendocrine histology should be the primary histologic classification as it is most likely to drive clinical outcome. In this review, we will refer to the small and large cell types as neuroendocrine carcinomas, (NECs) and to the well differentiated typical and atypical carcinoids as neuroendocrine tumors (NETs).

*Small cell neuroendocrine carcinomas.* Most neuroendocrine cancers of the cervix are small cell carcinomas. Small cell carcinomas are

characterized by high mitotic rate, extensive necrosis, frequent lymphovascular space involvement (LVSI) and a strong association with HPV 18 [4,5]. Notably, these tumors have a morphologic appearance similar to that seen in their counterparts of the lung. These highly aggressive tumors have a prognosis that is much worse than that for stage-comparable poorly differentiated squamous cell carcinoma of the cervix [6,7]. For the cervix, small cell carcinoma is synonymous with neuroendocrine small cell carcinoma. It is important to recognize that there are other small blue cell tumors that can arise in the cervix and mimic small cell carcinoma and these include 1) basaloid squamous cell carcinoma, 2) embryonal rhabdomyosarcoma, 3) lymphoma, and 4) undifferentiated carcinoma arising from the lower uterine segment. These can usually be excluded by immunohistochemical analysis. In addition, one must differentiate small cell neuroendocrine carcinomas from poorly differentiated squamous cell carcinoma (SCC) with neuroendocrine features. Consideration of therapies that would be used in small cell carcinomas has previously been proposed, but has not been validated by subsequent literature [8].

**Large cell neuroendocrine carcinomas.** Large cell NECs are poorly differentiated, have a high mitotic rate, extensive necrosis, LVSI, and are aggressive. Neuroendocrine differentiation is necessary for diagnosis [9,10].

#### Diagnosis

Small cell carcinomas account for up to 2% of cervical carcinomas [3,11–13]. There appears to be an increasing incidence of these tumors, which is likely due to increasing recognition and diagnostic accuracy [2,10]. Median age of diagnosis is in the fifth decade (range 21–87 years). The usual presenting symptom is vaginal bleeding, and a cervical mass can often be identified on exam. Some patients have an abnormal Pap smear [14]. In rare cases, patients may present with clinical or biochemical evidence of ectopic hormone production, including corticotropin (Cushing's syndrome), vasopressin (SIADH), insulin (hypoglycemia), serotonin (carcinoid syndrome), parathormone (hypercalcemia) or myasthenia gravis [15]. The diagnosis can be made on cervical biopsy; however, the limited amount of tissue obtained may yield a diagnosis of poorly differentiated cervical cancer, and the neuroendocrine component is sometimes recognized only later, following a hysterectomy.

The staging of NECs of the cervix follows that for traditional cervical cancer [16]. However, it is important to recognize the increased risk for LVSI and high rate of extrapelvic recurrences which correlates with a poor prognosis [13,17,18]. For example, early lymphatic spread to the regional lymph nodes was noted in 40% of stage IB small cell cancers <3 cm in diameter, and 60% of small cell carcinomas demonstrated LVSI at the time of diagnosis. Mean time to recurrence was 19.9 months. Bone, supraclavicular lymph nodes, and lung were the most common sites of extrapelvic disease spread. Radiographic evaluation should generally include either a CT or PET/CT scan. Given the high rate of distant metastatic spread, PET/CT imaging may be reasonable to consider [19,20]. Head CT is not required on initial evaluation for small cell tumors of the cervix. Hoskins et al. found no cranial metastases on initial patient presentation in their 14-year retrospective experience [21].

#### Management

Treatment considerations for small cell and large cell NEC variants of the cervix take into account the treatment options for cervical cancer, and draw on the data for treating small cell lung cancer. Recent data supports the use of platinum with or without etoposide in small cell and large cell NEC to improve survival [10,22,23]. In the lung, clinical outcome for small cell carcinoma is associated with disease extent. Surgery is primarily used either to achieve a diagnosis, or for resection of limited stage disease [23]. Historically, radiation was the standard primary approach for limited stage disease; however, recent retrospective data suggests that surgery may yield improved clinical

outcomes [24,25]. When radiation is used, it is typically given with concurrent etoposide/cisplatin. For advanced stage disease, metastatic sites are treated with platinum-based combination chemotherapy. While initial response rates are high (50–79%), recurrent or progressive chemoresistant disease frequently develops [23]. Vincristine/doxorubicin/cyclophosphamide and topotecan are considered as alternate or second-line therapies extrapolating from small cell lung cancer [26,27].

**Prognostic factors.** Advanced stage, tumor size, presence and number of lymph node metastases, pure small cell histology, and smoking have been linked to a worse clinical outcome for small cell cervical cancer [14,28–32]. In one study, all survivors had primary tumors less than 4 cm and no clinical evidence of lymph node metastasis [30]. As with small cell lung cancer, Chan et al. found smoking to be a significant prognostic factor for cervical NECs [15,33]. Smoking causes a lower oxygen saturation, which may negatively impact the effect of radiation. In addition, in vitro studies have shown that nicotine can serve as a growth factor for small cell cancers [34].

For limited stage small cell lung cancer, 20% of cases are long-term survivors [23]. In comparison, small cell cervical cancers have a reported 5-year survival of 36% [32]. Approximately half of cases are an early clinical stage, 41% stage I and 20% stage II, and approximately 50% have positive nodes at diagnosis [10]. For early stage disease treated with multi-modality regimens, recent reports have achieved an 80% 3-year disease free survival [21,35].

#### Early stage disease

**Surgery.** Surgery is an option for early stage disease and studies have included radical hysterectomy with regional lymphadenectomy as a component of the primary management [14,28–30,32,35–37]. Most studies report long-term survival only for those patients that have undergone surgical resection when performed in the context of a multi-modality treatment approach with adjuvant chemotherapy.

**Chemoradiation.** There are no prospective data to compare surgery with primary chemoradiation for small resectable cervical NECs. For advanced disease or non-surgical candidates, chemoradiation is reasonable. Patients with evidence of lymphadenopathy or FDG-avid nodal basins may also be candidates for primary chemoradiation. To extrapolate from lung cancer regimens, chemoradiation with etoposide/cisplatin (EP) concurrent with pelvic radiation is appropriate. Hoskins et al. reported successful treatment of cervical small cell carcinoma using chemoradiation (with EP) for stage IA–IVB disease [21]. Distant disease recurrence was the most common (28%) type of recurrence, and clinical outcome correlated with initial disease extent.

**Chemotherapy.** Many authors have supported the use of chemotherapy as part of a multimodality treatment approach for small cell cervical cancer over the last 20 years [28,31,37–42]. For early stage disease, patients with complete surgical resection should be considered for adjuvant chemotherapy. Chang reported a 5-year survival of 68% for patients who received vincristine, adriamycin, and cyclophosphamide alternating with cisplatin and etoposide (VAC/PE) regimen compared to 33% for those treated with cisplatin, vinblastine, and bleomycin (PVB) combination ( $p=0.0078$ ) [31]. Boruta et al. reported that post-operative chemotherapy, either with EP or VAC/PE was associated with a significant survival advantage. Adjuvant chemotherapy provided a survival advantage for patients either with or without lymph node metastasis. There was no additional survival advantage with the addition of radiotherapy [28]. Recently, Zivanovic demonstrated a strikingly similar benefit of adjuvant chemotherapy. In his report, early stage patients who received post-operative EP experienced an 83% 3-year recurrence-free survival, compared to 0% for those who did not receive adjuvant chemotherapy [35]. Notably, EP regimens are generally preferred over VAC-containing regimens because they are less toxic

[43,44]. Some studies have been unable to demonstrate a benefit to adjuvant chemotherapy, perhaps related to limited sample size and non-standardized regimens [14,37]. For example, Lee et al. reported on a trend in favor of post-operative chemotherapy and concluded that primary radical surgery followed by adjuvant chemotherapy is the preferred treatment modality for patients with early stage disease [37]. The propensity for lymph node metastasis and distant recurrence supports this approach.

Some authors have proposed the use of neoadjuvant chemotherapy [45,46]. Chang demonstrated a complete response in 6 out of 7 patients that received VAC/PE before hysterectomy; however, microscopic residual tumor was present in all cases. An additional three courses of chemotherapy were given following surgery. Subsequently, three patients had no evidence of disease at 16, 45, and 56 months of follow-up [45]. In contrast, Lee et al. reported no benefit in overall survival among 6 patients that received neoadjuvant treatment but the very small numbers makes it difficult to draw definitive conclusions [37].

**Pelvic radiation.** Sheets reported on 14 patients with early stage disease treated with surgery and adjuvant radiation for positive nodes or other high-risk features [29]. All patients recurred and all but two were dead at the time of the report. Sevin reported on 12 patients who underwent surgery with post-operative radiation for positive lymph node metastasis or close surgical margins [32]. Four of five patients who received radiation and who died of disease had pelvic recurrences. Of the entire study group, only those patients with small lesions who received adjuvant radiation were cured. These retrospective studies did not include any adjuvant chemotherapy, and do not appear to support the use of adjuvant radiation. Among the 23 patients reported by Chang, adjuvant radiation did not improve survival [31]. Lee reports that patients who received adjuvant radiation tended to have a worse prognosis than those who did not receive radiation with a 5-year survival of 40.2% versus 53.9% ( $p=0.09$ ). This finding was consistent even after excluding those patients with small ( $\leq 2$  cm) tumors [37].

**Whole brain radiation.** In small cell carcinoma of the lung, prophylactic brain irradiation is used for occult metastasis. In 2003, Weed noted that 25% (2/8) patients with apparent early stage small cell cervical cancer developed brain metastases and therefore proposed using prophylactic cranial irradiation (WBXRT) [47]. Hoskins et al. initially used WBXRT, but dropped it from their treatment regimen due to the low incidence of disease recurrent in the brain [21]. Data from M.D. Anderson Cancer Center reported that brain metastases were only seen concurrent with lung metastases [30]. WBXRT is therefore not routinely given for early stage disease, and brain imaging is generally only warranted in the presence of lung metastases.

**Advanced-stage and recurrent disease.** As reported by Hoskins et al., combination chemotherapy (EP) in addition to concurrent radiation can be used for advanced disease. Clinical stage was the only independent predictor for disease-free survival, 80% at 3 years for stage I/II, and 38% for stage III/IV. Distant sites of recurrence including lung and bone were more common (28%) than local failure (13%) [21]. Patients with widespread metastatic disease or recurrent disease can be treated with EP or VAC/PE regimens similar to those used in the treatment of small cell neuroendocrine carcinomas of the lung.

**Management algorithm.** In 2003, Chan proposed a management algorithm for small cell carcinoma of the cervix [14]. Given the above detailed review, modification of this approach is proposed as outlined in Fig. 1. We propose that for tumors less than 4 cm, radical hysterectomy with lymphadenectomy be performed with consideration of etoposide/platinum based therapies in the adjuvant setting. Tumors larger than 4 cm can be considered for a neoadjuvant approach with systemic platinum based therapies followed by a localized treatment based approach (including surgery) if the disease

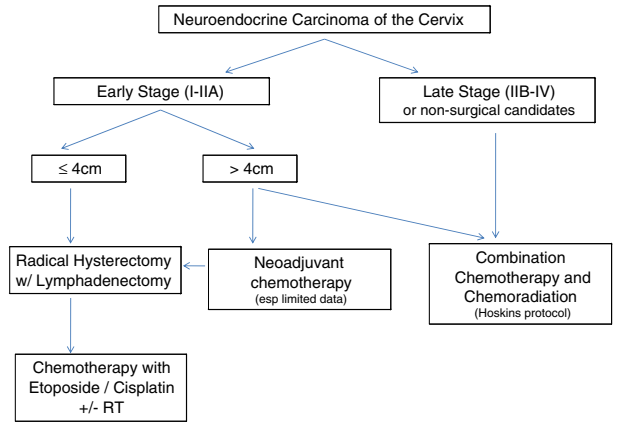


Fig. 1. Management algorithm for neuroendocrine carcinoma (NEC) of the cervix.

remains limited. In late stage or non-surgical candidates, combination chemotherapy (EP) with RT for local control should be considered. In sum, multimodality treatment appears to convey the best outcomes for this disease. Recognizing the lack of prospective randomized control trials, it is important to realize that individualized treatment of these challenging cases is appropriate.

**Surveillance.** Frequent clinical evaluation including symptom review and pelvic exam is appropriate. Given the potential for lung, brain or bony metastasis in addition to the risk of local recurrence, assessment should include a review of systems pertinent to these anatomic sites. Periodic full body imaging with either CT or PET/CT to evaluate for distant metastatic disease is appropriate. Brain imaging either with head CT or MRI should be considered if neurologic symptoms, mental status changes, or pulmonary metastases are identified.

#### Future research

As clinical research in small cell lung cancer evaluates new chemotherapy regimens, application of such new treatments may be appropriate to patients with small cell cervical cancer. Chemotherapy treatments such as temozolomide [48] and multiple molecular targets for treatment of NECs have been identified and are in clinical trials. Potential therapeutic targets include CD56, a neural cell adhesion molecule that is expressed by neuroendocrine cancers. A monoclonal antibody for CD56, linked to the cytotoxic compound DM-1 is in phase II trials. Src kinase, a tyrosine kinase, which has differential expression in both small cell and non-small cell lung cancer, is another potential target. The hedgehog pathway and Bcl-2 represent other areas of investigation [23].

#### Small cell and large cell NECs of the ovary

Until recently, small cell carcinoma of the ovary (SCCO) was grouped within the NETs of the ovary, however as they lack neuroendocrine differentiation it is best to consider them as a distinct entity. The histogenesis of SCCO remains an enigma [49]. The rarer non-small cell neuroendocrine carcinoma (NSCNEC) is also known as a large cell neuroendocrine carcinoma (LCNEC) and to date, only 35 cases of NSCNEC of the ovary have been reported. These tumors are typically admixed with other histologic subtypes and are generally associated with poor patient outcomes. The SCCO can be divided into hypercalcemic (SCCOHT) and pulmonary type (SCCOPT). Fewer than 300 SCCOs have been reported and they typically occur in young women with the median age being 23.9 years. As with the NSCNEC, these tumors are typically associated with a poor prognosis. Recognizing the paucity of data, a combination of surgical resection and etoposide/platinum therapy has been employed.



### Small cell carcinoma of the uterus

There are limited reported cases of endometrial small cell carcinoma in the English literature [50,51] and diagnosis requires at least one positive neuroendocrine marker [50]. Abnormal bleeding is the primary presenting symptom, although some patients present with symptomatic metastases [52,53]. These tumors may be admixed with other endometrial malignancies [53]. Patients tend to present with advanced disease and have a poor prognosis recurring within 2 years of treatment. Of the limited long-term survivors with clinical information available, surgical resection followed by EP and radiation has been used [50,52–55].

### Small cell carcinoma of the vagina

Primary small cell carcinoma of the vagina is rare with less than 25 cases reported. The mean age at diagnosis is 59 years and women typically present with post-menopausal bleeding. These lesions have a propensity for early widespread dissemination, and 85% die within one year of diagnosis [56,57]. Only for small resectable lesions, should surgery be considered. Appropriate management can otherwise be adopted from that used to approach small cell carcinoma of the cervix.

### Small cell carcinoma of the vulva

There are case reports of neuroendocrine small cell cancer of the vulva; however, the majority may represent Merkel cell carcinoma, a neuroendocrine carcinoma of the skin. Both tumor types demonstrate neurosecretory granules and have an aggressive clinical course. The first priority should be to verify the diagnostic accuracy of the pathologic interpretation [58,59]. Surgical resection and multimodality treatment is reasonable to consider from the limited case reports.

### Well differentiated neuroendocrine tumors (NETs): Typical and atypical carcinoids

Well differentiated NETs are thought to arise from the neural crest and have enzymatic potential. Similar to the poorly differentiated small and large cell neuroendocrine carcinomas, immunohistochemistry with well differentiated neuroendocrine markers, such as chromogranin, synaptophysin, and neuron specific enolase, can facilitate a histologic diagnosis.

Tumors that develop from the neuroendocrine tissues of the aerodigestive, gynecologic, and genitourinary tracts are called carcinoid tumors, whereas tumors of the endocrine tissues of the pancreas are known as pancreatic endocrine tumors (PETs). Carcinoid tumors are typically well- to moderately differentiated NETs. These rare gynecologic tumors lack nuclear atypia, mitotic figures and necrosis. Given their degree of differentiation, their disease course is thought to be indolent; however, the rarity of this tumor type limits the data available on clinical outcomes [60,61].

Atypical carcinoid tumors demonstrate nuclear atypia, often demonstrate necrosis, and immunohistochemical evidence of neuroendocrine differentiation is required for the diagnosis. Their rarity limits the ability to assess their clinical behavior. If we extrapolate from the gastrointestinal NETs, the outcome is better than a poorly differentiated NEC but worse than a well-differentiated carcinoid tumor [62].

### Diagnosis and work-up

It is noteworthy that because NETs are often isodense with normal hepatic parenchyma, routine CT scans are of somewhat less value [63]. At the time of diagnosis, cross sectional imaging including either a CT triphasic or MRI are more appropriate techniques for imaging and

should be performed to evaluate the extent of the disease. Somatostatin analog scintigraphy, also known as an octreotide scan, should also be used to assess relevant receptor expression *in vivo* in order to predict who should be considered for somatostatin analog therapy. One report demonstrated that somatostatin receptor subtype 2 expression by <sup>111</sup>Inpentetreotide scintigraphy correlated with both tracer uptake and a better prognosis [64]. Patients with negative somatostatin scintigraphy scans should not be placed on somatostatin analogs. Octreotide negative tumors may have a higher response to chemotherapy treatment [65].

### Biochemical and cardiac monitoring

Unlike high grade neuroendocrine carcinomas, measurement of blood and urine markers may be helpful for monitoring well differentiated carcinoid tumors and can help diagnose hormone secreting tumors. 5-HIAA is the breakdown product of serotonin. In a patient with symptoms suggestive of a carcinoid syndrome (i.e. flushing and/or diarrhea) a 24 h urinary 5-HIAA should be collected. Elevated urinary 5-HIAA is highly specific for carcinoid tumors but is not particularly sensitive [66].

Plasma chromogranin A (CGA) is a more sensitive marker than urinary 5-HIAA in patients with carcinoid tumors. Levels are higher in patients with diffuse metastases than with localized disease or isolated hepatic involvement, and higher levels may be associated with a poorer prognosis [67,68].

The literature suggests that cardiac carcinoid syndrome is relatively common, occurring in 11–66% of patients with carcinoid syndrome [69,70], although these numbers seem to be trending down since the advent of somatostatin analog therapy, and it is less common in ovarian carcinoids [71]. Carcinoid heart disease is caused by the vasoactive substances produced by the tumor [72]. As the ovarian veins drain directly into the IVC or the renal vein, patients may also experience right sided heart disease in the absence of liver metastases. Most clinicians recommend a baseline echocardiogram in all patients with carcinoid syndrome, and in those who develop clinical features of right heart failure, in case valve replacement surgery would be an option.

### Carcinoid of the ovary

Primary carcinoid tumors of the ovary account for less than 5% of all carcinoid tumors and for less than 0.1% of all ovarian neoplasms [73]. The median age of diagnosis is 55 years of age (range 17–83 years) [74]. These tumors are typically classified as germ cell tumors of the ovary and can be divided into four categories: 1) insular, 2) trabecular, 3) mucinous, and 4) mixed. Primary carcinoid tumors typically behave in a benign fashion. Most ovarian carcinoids contain the insular pattern, are unilateral and early stage [75]. Strumal carcinoid has only recently been recognized as a distinct entity as thyroid tissue with carcinoid tumor. It is important to establish that these are not metastatic carcinoids; the insular, followed by the trabecular are the most common subtypes that metastasize to the ovary. Given the rarity of the disease, it is also critical to rule out a metastatic GI primary that could have metastasized to the ovary, and tend to present as bilateral ovarian metastases.

The majority of women with primary ovarian carcinoid tumors are found incidentally on cross sectional or ultrasound imaging. Rarely, they may also present with abdominal pain, constipation, hirsutism and a pelvic mass. The constipation and hirsutism are thought to be due to the release of Peptide YY (PYY) by the tumors. PYY is a gastrointestinal peptide that is present mainly in the endocrine cells of the distal intestine and inhibits motility [76,77]. Some of the more differentiated tumors may present with carcinoid syndrome. For women who present with a stage I primary ovarian carcinoid, the prognosis is excellent, with greater than 90% survival [73]. For women

with more advanced disease, the prognosis is poor [74,75]. Octreotide has been used in some reports [78]. The most recent Neuroendocrine Tumor National Comprehensive Cancer Network (NCCN) guidelines do not include ovarian carcinoid or ovarian NETs [www.nccn.org, version 2.2009].

One large series (329 cases) has been published, which was comprised of cases from 273 articles in 11 different languages. These authors separated the carcinoids into those with an associated dermoid (Group A; n = 189) and those without (Group B; n = 140). The tumors in Group B were larger (89 mm versus 45 mm), associated with a higher rate of overall (22.1% versus 5.8%) and hepatic (15.0% versus 2.1%) metastases, had a higher rate of carcinoid syndrome (22.9% versus 13.8%), and poorer 5-year survival (84% versus 93.7%) [79], thus providing some prognostic information.

#### *Insular carcinoid*

This is the most common type of ovarian carcinoid, occurring in patients between 40 and 80 years of age. The majority present with a pelvic mass and approximately 40% will have clinical evidence of carcinoid syndrome [74,75]. Those who present with carcinoid syndrome typically have larger masses (>7 cm) [75,80]. It is important to differentiate a primary lesion from an ovarian metastasis. As noted above, metastatic carcinoid is frequently bilateral [81]. These tumors are typically slow growing. For those limited to the ovary, the 10-year survival is 100% if unilateral. For women with advanced stage disease the 5-year survival is 33% [74].

#### *Trabecular carcinoid*

The second most common carcinoid tumor (about one-third as common as insular tumors), occurs in women between 30 and 70 years of age [82,83]. They are not typically associated with carcinoid syndrome, but may be associated with increased constipation due to PYY [76,77,84,85]. There have been no tumor related deaths reported.

#### *Mucinous carcinoid*

These rare carcinoid tumors occur in patients between 30 and 80 years of age. These tumors may be pure or may be associated with mature teratomas. Due to their rarity, one needs to consider that the ovarian tumor may be a metastasis from a gastrointestinal tumor. In the case of a mucinous carcinoid, an appendectomy should be performed to exclude the more common primary mucinous appendiceal carcinoid [86,87]. The overall survival of women with this disease appears to be very good with only 2 of 15 patients in the series by Baker et al. succumbing to the disease [87].

#### *Management: role of tumor resection and localized treatment options*

If one can extrapolate from the more common gastrointestinal neuroendocrine tumors, the typical management is surgical resection. The most recent neuroendocrine tumor NCCN guidelines recommend that the tumor be removed completely with the goal of attaining negative margins. In addition, if the diagnosis is known or suspected preoperatively, octreotide (100–500 mcg SQ/IV every 6–12 h) should be administered immediately prior to and during the resection of the tumor to prevent the rare complication of carcinoid crisis [88]. Carcinoid crisis can occur in patients with the carcinoid syndrome (i.e., serotonin secreting tumors) and is characterized by profound flushing, extreme changes in blood pressure, bronchoconstriction, arrhythmias, and confusion or stupor. It can occur during induction of anesthesia. The administration of octreotide prior to general anesthesia prevents the carcinoid crisis from occurring.

There are no clear recommendations regarding surgical management of ovarian carcinoid or ovarian NETs. In the case of ovarian carcinoid tumors, fertility sparing surgery is permissible as these

tumors are generally unilateral and associated with a good prognosis. The surgical approach can include everything from fertility sparing surgery to radical debulking dependent on patient age and disease distribution [89–94].

The most common sites of metastatic disease include regional lymph nodes, liver, bones and lung. Most carcinoid tumors demonstrate a remarkable tropism for the liver. For this reason, liver lesions should be considered for resection to control tumor burden and the NCCN guidelines recommend that those lesions that are not resectable should be considered for cryotherapy, radiofrequency ablation [95,96] or regional embolization [97–99] upon progression. Bony metastases can be managed by localized radiotherapy with or without bisphosphonates.

#### *Role of adjuvant therapy*

There is no evidence to support the use of adjuvant therapy of any sort, either hormonal, chemotherapy, or radiation therapy for either gynecologic carcinoid tumors, resected pancreatic endocrine tumors or gastrointestinal carcinoid tumors.

#### *Advanced-stage and recurrent disease*

The majority of regimens follow those recommended for germ cell tumors, with many reports also advocating radiotherapy. However, it is difficult to estimate response rates and thus difficult to recommend one treatment strategy over another. The authors have chosen to focus on the data presented by the NCCN. Even though NCCN guidelines do not include rare (<5%) tumors and thus do not include ovarian carcinoid and NETs, the data presented is more rigorous and some early and late phase clinical trials have been completed. At this time, the NCCN panel recommends that patients with recurrent or unresectable carcinoid tumors who have no signs of carcinoid syndrome and are asymptomatic be observed until the disease becomes symptomatic; that they participate in a clinical trial; or that octreotide therapy be considered.

Octreotide is an eight amino acid synthetic analog of somatostatin, which was designed to bind with the somatostatin receptor. A depot long-acting release preparation of a once-monthly intramuscular injection of octreotide or a similar drug, lanreotide, can stabilize disease. One report showed a doubling of progression free survival when octreotide was compared to placebo in metastatic midgut carcinoid tumors [102]. They are also highly effective in treating hormonally-induced NET symptoms [85,100–108]. The dose and frequency can be slowly titrated until the patient's symptoms are controlled [104,105].

Alpha-interferon alone improves hormonal symptoms and induces tumor stabilization in up to 70% of NET patients and achieves an objective tumor response in 10% of patients [106]. However, due to its side effect profile (anorexia, weight loss, fatigue), alpha-interferon is rarely utilized [110].

Other chemotherapies which have been administered in the setting of recurrent, unresectable disease include doxorubicin, 5-fluorouracil, dacarbazine, actinomycin-D, cisplatin, etoposide and carboplatin. All of these agents have response rates ranging from 20–50% but the older studies citing these response rates are flawed by a lack of formal criteria for declaring an objective response, and the frequent use of such unreliable measures as perceived changes in physical examination or a drop in hormone level as the basis for declaring a major response. Thus, the true objective response rate may be closer to 10–15% [111–114].

#### *Future research*

VEGF and mTOR inhibitors have been evaluated [109,115–121]. In a randomized phase II study of bevacizumab in carcinoid tumors of

the GI tract, there was an 18% response rate (RR) and a 16.5-month median progression free survival (PFS) [109]. Sunitinib was associated with a 2% and 17% RR (GI carcinoid and pancreatic NET, respectively) [115] and sorafenib was associated with a 7% and 11% RR [119] in patients with GI carcinoid and pancreatic NETs, respectively, illustrating difference in therapy response based on the organ of origin. Both of these agents were associated with more adverse events than bevacizumab.

mTOR inhibitors have also been investigated. Temsirolimus was evaluated in patients with NETs and was associated with a 5.6% RR and a median time to tumor progression of 6 months [116]. Another mTOR inhibitor, everolimus, was evaluated in a phase II study and was associated with an 8% RR, a 77% clinic benefit rate and a median PFS of 9 months [120]. Based on Phase II data, there have been several phase III trials in carcinoid tumors. RADIANT 2 was a randomized trial evaluating everolimus versus placebo in 390 patients with progressive carcinoid tumors. Median PFS was 16.4 months versus 11.3 months. However, the PFS did not achieve its primary endpoint of PFS based on adjudicated central radiologic review. Analyses that adjusted for imbalances in baseline characteristics, however, showed everolimus plus octreotide LAR decreased the likelihood of disease progression [121].

Another trial is evaluating octreotide + bevacizumab versus octreotide + interferon alpha-2b in 283 patients with poor prognosis carcinoid. As this data matures, it may be reasonable to extrapolate to women with advanced ovarian carcinoid tumors.

## Summary and recommendations

### Questions

1. Given the high rate of metastatic spread, what is the role of surgery in the management of small cell cervical cancer? Hysterectomy is sometimes required to secure the diagnosis of small cell carcinoma of the cervix. In some cases, the limited tissue available on cervical biopsy yields only the diagnosis of a poorly differentiated carcinoma. For those patients in whom the diagnosis is known, hysterectomy can be considered for early stage disease as part of a multi-modality therapeutic strategy. Adjuvant chemotherapy with etoposide/cisplatin, even without evidence of nodal metastasis, should be considered given the high rate of distant recurrence.
2. What imaging studies are most appropriate for the evaluation and surveillance of neuroendocrine tumors? For the high grade neuroendocrine carcinomas (small and large cell types) arising from the cervix, CT or PET/CT is appropriate. Brain imaging is not required in the initial evaluation or in routine surveillance unless neurologic symptoms or pulmonary metastases are identified. For well differentiated carcinoid and atypical carcinoids, an octreotide scan is important to check for the presence of the somatostatin receptor as the results have implications regarding treatment and prognosis. Cross sectional imaging including either CT triphasic or MRI should be considered. Patients with octreotide negative carcinoid tumors may have a worse prognosis and should be considered for conventional cytotoxic therapy.
3. How can we optimize combined modality treatment? Full dose combination chemotherapy with etoposide and cisplatin is recommended for neuroendocrine carcinomas of the cervix, both for those patients with complete surgical resection as for patients who undergo chemoradiation.
4. What lessons can be learned from small cell carcinomas of the lung? Multiple parallels in histology and clinical activity can be identified between neuroendocrine carcinomas primary to the lung and high grade small cell neuroendocrine carcinoma primary to the gynecologic tract. An awareness of these similarities as well as the on-going research in lung cancer can drive improved outcomes for gynecologic cancer patients over time.

## Conflict of interest statement

The authors of this review have no conflict of interests to declare.

## Acknowledgments

The authors would like to thank the members of the Clinical Practice Committee with specific recognition of Dr. David Moore, Chair, Dr. Randall Gibb, Dr. Mitchell Edelson, Mary Eiken (SGO administration) and Melissa Finnegan (SGO administration).

## References

- [1] Moertel C, Kvols L, O'Connell M, Rubin J. Treatment of neuroendocrine carcinomas with combined etoposide and cisplatin: evidence of major therapeutic activity in the anaplastic variants of these neoplasms. *Cancer* 1991;68:227–32.
- [2] Yao JC, Hassan M, Phan A, Dagohoy C, Leary C, Mares JE, et al. One hundred years after "carcinoid": epidemiology of and prognostic factors for neuroendocrine tumors in 35,825 cases in the United States. *J Clin Oncol* 2008;26:3063–72.
- [3] Albores-Saavedra J, Gersell D, Gilks CB, Henson DE, Lindberg G, Santiago H, et al. Terminology of endocrine tumors of the uterine cervix: results of a workshop sponsored by the College of American Pathologists and the National Cancer Institute. *Arch Pathol Lab Med* 1997;121:34–9.
- [4] Ambros RA, Park JS, Shah KV, Kurman RJ. Evaluation of histologic, morphometric, and immunohistochemical criteria in the differential diagnosis of small cell carcinomas of the cervix with particular reference to human papillomavirus types 16 and 18. *Mod Pathol* 1991;4:586–93.
- [5] Stoler MH, Mills SE, Gersell DJ, Walker AN. Small-cell neuroendocrine carcinoma of the cervix. A human papillomavirus type 18-associated cancer. *Am J Surg Pathol* 1991;15:28–32.
- [6] Walker AN, Mills SE, Taylor PT. Cervical neuroendocrine carcinoma: a clinical and light microscopic study of 14 cases. *Int J Gynecol Pathol* 1988;7:64–74.
- [7] Gersell DJ, Mazoujian G, Mutch DG, Rudloff MA. Small-cell undifferentiated carcinoma of the cervix. A clinicopathologic, ultrastructural, and immunocytochemical study of 15 cases. *Am J Surg Pathol* 1988;12:684–98.
- [8] Lee SW, Nam JH, Kim DY, Kim JH, Kim KR, Kim YM, et al. Unfavorable prognosis of small cell neuroendocrine carcinoma of the uterine cervix: a retrospective matched case–control study. *Int J Gynecol Cancer* 2010;20:411–6.
- [9] Gilks CB, Young RH, Gersell DJ, Clement PB. Large cell neuroendocrine [corrected] carcinoma of the uterine cervix: a clinicopathologic study of 12 cases. *Am J Surg Pathol* 1997;21:905–14.
- [10] McCusker ME, Cote TR, Clegg LX, Tavassoli FJ. Endocrine tumors of the uterine cervix: incidence, demographics, and survival with comparison to squamous cell carcinoma. *Gynecol Oncol* 2003;88:333–9.
- [11] Scully RE, Aguirre P, DeLellis RA. Argypophilia, serotonin, and peptide hormones in the female genital tract and its tumors. *Int J Gynecol Pathol* 1984;3:51–70.
- [12] Miller B, Dockter M, el Torky M, Photopoulos G. Small cell carcinoma of the cervix: a clinical and flow-cytometric study. *Gynecol Oncol* 1991;42:27–33.
- [13] Van Nagell Jr JR, Donaldson ES, Wood EG, Maruyama Y, Utley J. Small cell cancer of the uterine cervix. *Cancer* 1977;40:2243–9.
- [14] Chan JK, Loizzi V, Burger RA, Rutgers J, Monk BJ. Prognostic factors in neuroendocrine small cell cervical carcinoma: a multivariate analysis. *Cancer* 2003;97:568–74.
- [15] Hirahatake K, Hareyama H, Kure R, Kawaguchi I, Yamaguchi J, Sakuragi N, et al. Cytologic and hormonal findings in a carcinoid tumor of the uterine cervix. *Acta Cytol* 1990;34:119–24.
- [16] Pecorelli S, Zigliani L, Odicino F. Revised FIGO staging for carcinoma of the cervix. *Int J Gynaecol Obstet* 2009;105:107–8.
- [17] Wentz WB, Reagan JW. Survival in cervical cancer with respect to cell type. *Cancer* 1959;12:384–8.
- [18] van Nagell Jr JR, Powell DE, Gallion HH, Elliott DG, Donaldson ES, Carpenter AE, et al. Small cell carcinoma of the uterine cervix. *Cancer* 1988;62:1586–93.
- [19] Baum RP, Swietaszczyk C, Prasad V. FDG-PET/CT in lung cancer: an update. *Front Radiat Ther Oncol* 2010;42:15–45.
- [20] Lee YJ, Cho A, Cho BC, Yun M, Kim SK, Chang J, et al. High tumor metabolic activity as measured by fluorodeoxyglucose positron emission tomography is associated with poor prognosis in limited and extensive stage small-cell lung cancer. *Clin Cancer Res* 2009;15:2426–32.
- [21] Hoskins PJ, Swenerton KD, Pike JA, Lim P, Aquino-Parsons C, Wong F, et al. Small-cell carcinoma of the cervix: fourteen years of experience at a single institution using a combined-modality regimen of involved-field irradiation and platinum-based combination chemotherapy. *J Clin Oncol* 2003;21:3495–501.
- [22] Embry JR, Kelly MG, Post MD, Spillman MA. Large cell neuroendocrine carcinoma of the cervix: prognostic factors and survival advantage with platinum chemotherapy. *Gynecol Oncol* 2011;120:444–8.
- [23] Dowell JE. Small cell lung cancer: are we making progress? *Am J Med Sci* 2010;339:68–76.
- [24] Brock MV, Hooker CM, Syphard JE, Westra W, Xu L, Alberg AJ, et al. Surgical resection of limited disease small cell lung cancer in the new era of platinum chemotherapy: its time has come. *J Thorac Cardiovasc Surg* 2005;129:64–72.
- [25] Bischof M, Debus J, Herfarth K, Muley T, Kappes J, Storz K, et al. Surgery and chemotherapy for small cell lung cancer in stages I–II with or without radiotherapy. *Strahlenther Onkol* 2007;183:679–84.



- [26] Shepherd FA, Evans WK, MacCormick R, Feld R, Yau JC. Cyclophosphamide, doxorubicin, and vincristine in etoposide- and cisplatin-resistant small cell lung cancer. *Cancer Treat Rep* 1987;71:941–4.
- [27] O'Brien ME, Ciuleanu TE, Tsekov H, Shparlyk Y, Cucevia B, Juhasz G, et al. Phase III trial comparing supportive care alone with supportive care with oral topotecan in patients with relapsed small-cell lung cancer. *J Clin Oncol* 2006;24:5441–7.
- [28] Boruta II DM, Schorge JO, Duska LA, Crum CP, Castrillon DH, Sheets EE. Multimodality therapy in early-stage neuroendocrine carcinoma of the uterine cervix. *Gynecol Oncol* 2001;81:82–7.
- [29] Sheets EE, Berman ML, Hrontas CK, Liao SY, DiSaia PJ. Surgically treated, early-stage neuroendocrine small-cell cervical carcinoma. *Obstet Gynecol* 1988;71:10–4.
- [30] Viswanathan AN, Deavers MT, Jhingran A, Ramirez PT, Levenback C, Eifel PJ. Small cell neuroendocrine carcinoma of the cervix: outcome and patterns of recurrence. *Gynecol Oncol* 2004;93:27–33.
- [31] Chang TC, Lai CH, Tseng CJ, Hsueh S, Huang KG, Chou HH. Prognostic factors in surgically treated small cell cervical carcinoma followed by adjuvant chemotherapy. *Cancer* 1998;83:712–8.
- [32] Sevin BU, Method MW, Nadjji M, Lu Y, Averette HA. Efficacy of radical hysterectomy as treatment for patients with small cell carcinoma of the cervix. *Cancer* 1996;77:1489–93.
- [33] Videtic GM, Stitt LW, Dar AR, Kocha WI, Tomiak AT, Truong PT, et al. Continued cigarette smoking by patients receiving concurrent chemoradiotherapy for limited-stage small-cell lung cancer is associated with decreased survival. *J Clin Oncol* 2003;21:1544–9.
- [34] Novak J, Escobedo-Morse A, Kelley K, Boose D, Kautzman-Eades D, Meyer M, et al. Nicotine effects on proliferation and the bombesin-like peptide autocrine system in human small cell lung carcinoma SHP77 cells in culture. *Lung Cancer* 2000;29:1–10.
- [35] Zivanovic O, Leitao Jr MM, Park KJ, Zhao H, Diaz JP, Konner J, et al. Small cell neuroendocrine carcinoma of the cervix: analysis of outcome, recurrence pattern and the impact of platinum-based combination chemotherapy. *Gynecol Oncol* 2009;112:590–3.
- [36] Trinh XB, Bogers JJ, Van Marck EA, Tjalma WA. Treatment policy of neuroendocrine small cell cancer of the cervix. *Eur J Gynaecol Oncol* 2004;25:40–4.
- [37] Lee JM, Lee KB, Nam JH, Ryu SY, Bae DS, Park JT, et al. Prognostic factors in FIGO stage IB–IIA small cell neuroendocrine carcinoma of the uterine cervix treated surgically: results of a multi-center retrospective Korean study. *Ann Oncol* 2008;19:321–6.
- [38] O'Hanlan KA, Goldberg GL, Jones JG, Runowicz CD, Ehrlich L, Rodriguez-Rodriguez L. Adjuvant therapy for neuroendocrine small cell carcinoma of the cervix: review of the literature. *Gynecol Oncol* 1991;43:167–72.
- [39] Lewandowski GS, Copeland LJ. A potential role for intensive chemotherapy in the treatment of small cell neuroendocrine tumors of the cervix. *Gynecol Oncol* 1993;48:127–31.
- [40] Collinet P, Lanvin D, Declerck D, Chevalier-Place A, Leblanc E, Querleu D. Neuroendocrine tumors of the uterine cervix. Clinicopathologic study of five patients. *Eur J Obstet Gynecol Reprod Biol* 2000;91:51–7.
- [41] Abulafia O, Sherer DM. Adjuvant chemotherapy in stage IB neuroendocrine small cell carcinoma of the cervix. *Acta Obstet Gynecol Scand* 1995;74:740–4.
- [42] Morris M, Gershenson DM, Eifel P, Silva EG, Mitchell MF, Burke TW, et al. Treatment of small cell carcinoma of the cervix with cisplatin, doxorubicin, and etoposide. *Gynecol Oncol* 1992;47:62–5.
- [43] Fukuoka M, Furuse K, Saijo N, Nishiwaki Y, Ikegami H, Tamura T, et al. Randomized trial of cyclophosphamide, doxorubicin, and vincristine versus cisplatin and etoposide versus alternation of these regimens in small-cell lung cancer. *J Natl Cancer Inst* 1991;83:855–61.
- [44] Roth BJ, Johnson DH, Einhorn LH, Schacter LP, Cherng NC, Cohen HJ, et al. Randomized study of cyclophosphamide, doxorubicin, and vincristine versus etoposide and cisplatin versus alternation of these two regimens in extensive small-cell lung cancer: a phase III trial of the Southeastern Cancer Study Group. *J Clin Oncol* 1992;10:282–91.
- [45] Chang TC, Hsueh S, Lai CH, Tseng CJ, Lee KF, Huang KG, et al. Phase II trial of neoadjuvant chemotherapy in early-stage small cell cervical cancer. *Anticancer Drugs* 1999;10:641–6.
- [46] Bermudez A, Vighi S, Garcia A, Sardi J. Neuroendocrine cervical carcinoma: a diagnostic and therapeutic challenge. *Gynecol Oncol* 2001;82:32–9.
- [47] Weed Jr JC, Graff AT, Shoup B, Tawfik O. Small cell undifferentiated (neuroendocrine) carcinoma of the uterine cervix. *J Am Coll Surg* 2003;197:44–51.
- [48] Ekeblad S, Sundin A, Janson ET, Welin S, Granberg D, Kindmark H, et al. Temozolomide as monotherapy is effective in treatment of advanced malignant neuroendocrine tumors. *Clin Cancer Res* 2007;13:2986–91.
- [49] Young RH, Goodman A, Penson RT, Russell AH, Uppot RN, Tambouret RH. Case records of the Massachusetts General Hospital. Case 8–2010. A 22-year-old woman with hypercalcemia and a pelvic mass. *N Engl J Med* 2010;362:1031–40.
- [50] van Hoeven KH, Hudock JA, Woodruff JM, Suhland MJ. Small cell neuroendocrine carcinoma of the endometrium. *Int J Gynecol Pathol* 1995;14:21–9.
- [51] Crowder S, Tuller E. Small cell carcinoma of the female genital tract. *Semin Oncol* 2007;34:57–63.
- [52] Katahira A, Akahira J, Niikura H, Ito K, Moriya T, Matsuzawa S, et al. Small cell carcinoma of the endometrium: report of three cases and literature review. *Int J Gynecol Cancer* 2004;14:1018–23.
- [53] Huntsman DG, Clement PB, Gilks CB, Scully RE. Small-cell carcinoma of the endometrium. A clinicopathological study of sixteen cases. *Am J Surg Pathol* 1994;18:364–75.
- [54] Manivel C, Wick MR, Sibley RK. Neuroendocrine differentiation in mullerian neoplasms. An immunohistochemical study of a “pure” endometrial small-cell carcinoma and a mixed mullerian tumor containing small-cell carcinoma. *Am J Clin Pathol* 1986;86:438–43.
- [55] Olson N, Twiggs L, Sibley R. Small-cell carcinoma of the endometrium: light microscopic and ultrastructural study of a case. *Cancer* 1982;50:760–5.
- [56] Kaminski JM, Anderson PR, Han AC, Mitra RK, Rosenblum NG, Edelson MI. Primary small cell carcinoma of the vagina. *Gynecol Oncol* 2003;88:451–5.
- [57] Elsaleh H, Bydder S, Cassidy B, Thompson J. Small cell carcinoma of the vagina. *Australas Radiol* 2000;44:336–7.
- [58] Cliby W, Soisson AP, Berchuck A, Clarke-Pearson DL. Stage I small cell carcinoma of the vulva treated with vulvectomy, lymphadenectomy, and adjuvant chemotherapy. *Cancer* 1991;67:2415–7.
- [59] Finan MA, Barre G. Bartholin's gland carcinoma, malignant melanoma and other rare tumours of the vulva. *Best Pract Res Clin Obstet Gynaecol* 2003;17:609–33.
- [60] Albores-Saavedra J, Larraza O, Poucell S, Rodriguez Martinez HA. Carcinoid of the uterine cervix: additional observations on a new tumor entity. *Cancer* 1976;38:2328–42.
- [61] Albores-Saavedra J, Rodriguez-Martinez HA, Larraza-Hernandez O. Carcinoid tumors of the cervix. *Pathol Annu* 1979;14(Pt 1):273–91.
- [62] Strosberg J, Nasir A, Coppola D, Wick M, Kvolis L. Correlation between grade and prognosis in metastatic gastroenteropancreatic neuroendocrine tumors. *Hum Pathol* 2009;40:1262–8.
- [63] Reidy DL, Tang LH, Saltz LB. Treatment of advanced disease in patients with well-differentiated neuroendocrine tumors. *Nat Clin Pract Oncol* 2009;6:143–52.
- [64] Asnacios A, Courbon F, Rochemaux P, et al. Indium-111-pentetreotide scintigraphy and somatostatin receptor subtype 2 expression: new prognostic factors for malignant well-differentiated endocrine tumors. *J Clin Oncol* 2008;26:963–70.
- [65] Moertel CG, Kvolis LK, O'Connell MJ, Rubin J. Treatment of neuroendocrine carcinomas with combined etoposide and cisplatin. Evidence of major therapeutic activity in the anaplastic variants of these neoplasms. *Cancer* 1991;68:227–32.
- [66] Feldman JM, O'Dorisio TM. Role of neuropeptides and serotonin in the diagnosis of carcinoid tumors. *Am J Med* 1986;81:41–8.
- [67] Taupenot L, Harper KL, O'Connor DT. The chromogranin-secretogranin family. *N Engl J Med* 2003;348:1134–49.
- [68] Campana D, Nori F, Piscitelli L, Morselli-Labate AM, Pezzilli R, Corinaldesi R, et al. Chromogranin A: is it a useful marker of neuroendocrine tumors? *J Clin Oncol* 2007;25:1967–73.
- [69] Jacobsen MB, Nitter-Hauge S, Bryde PE, Hanssen LE. Cardiac manifestations in mid-gut carcinoid disease. *Eur Heart J* 1995;16:263–8.
- [70] Anderson AS, Krauss D, Lang R. Cardiovascular complications of malignant carcinoid disease. *Am Heart J* 1997;134:693–702.
- [71] Chaowalit N, Connolly HM, Schaff HV, Webb MJ, Pellikka PA. Carcinoid heart disease associated with primary ovarian carcinoid tumor. *Am J Cardiol* 2004;93:1314–5.
- [72] Kulke MH, Mayer RJ. Carcinoid tumors. *N Engl J Med* 1999;340:858–68.
- [73] Modlin IM, Lye KD, Kidd M. A 5-decade analysis of 13,715 carcinoid tumors. *Cancer* 2003;97:934–59.
- [74] Davis KP, Hartmann LK, Keeney GL, Shapiro H. Primary ovarian carcinoid tumors. *Gynecol Oncol* 1996;61:259–65.
- [75] Robboy SJ, Norris HJ, Scully RE. Insular carcinoid primary in the ovary. A clinicopathologic analysis of 48 cases. *Cancer* 1975;36:404–18.
- [76] Motoyama T, Katayama Y, Watanabe H, Okazaki E, Shibuya H. Functioning ovarian carcinoids induce severe constipation. *Cancer* 1992;70:513–8.
- [77] Matsuda K, Maehama T, Kanazawa K. Strumal carcinoid tumor of the ovary: a case exhibiting severe constipation associated with PYY. *Gynecol Oncol* 2002;87:143–5.
- [78] Vergani D, Massironi L, Lombardi F, Fiorentini C. Carcinoid heart disease from ovarian primary presenting with acute pericarditis and biventricular failure. *Heart* 1998;80:623–6.
- [79] Soga J, Osaka M, Yakuwa Y. Carcinoids of the ovary: an analysis of 329 reported cases. *J Exp Clin Cancer Res* 2000;19:271–80.
- [80] Robboy SJ. Insular carcinoid of ovary associated with malignant mucinous tumors. *Cancer* 1984;54:2273–6.
- [81] Robboy SJ, Scully RE, Norris HJ. Carcinoid metastatic to the ovary. A clinicopathologic analysis of 35 cases. *Cancer* 1974;33:798–811.
- [82] Talerman A, Evans MI. Primary trabecular carcinoid tumor of the ovary. *Cancer* 1982;50:1403–7.
- [83] Robboy SJ, Scully RE, Norris HJ. Primary trabecular carcinoid of the ovary. *Obstet Gynecol* 1977;49:202–7.
- [84] Yaegashi N, Tsuike A, Shimizu T, Kobayashi N, Sato S, Namiki T, et al. Ovarian carcinoid with severe constipation due to peptide YY production. *Gynecol Oncol* 1995;56:302–6.
- [85] Kawano K, Ushijima K, Fujimoto T, Komai K, Kamura T. Peptide YY producing strumal carcinoid of the ovary as the cause of severe constipation with contralateral epithelial ovarian cancer. *J Obstet Gynaecol Res* 2007;33:392–6.
- [86] Alenghat E, Okagaki T, Talerman A. Primary mucinous carcinoid tumor of the ovary. *Cancer* 1986;58:777–83.
- [87] Baker PM, Oliva E, Young RH, Talerman A, Scully RE. Ovarian mucinous carcinoids including some with a carcinomatous component: a report of 17 cases. *Am J Surg Pathol* 2001;25:557–68.
- [88] Oberg K, Kvolis L, Caplin M, Delle Fave G, de Herder W, Rindi G, et al. Consensus report on the use of somatostatin analogs for the management of neuroendocrine tumors of the gastroenteropancreatic system. *Ann Oncol* 2004;15:966–73.
- [89] Harrison ML, Hoskins P, du Bois A, Quinn M, Rustin GJ, Ledermann JA, et al. Small cell of the ovary, hypercalcemic type—analysis of combined experience and recommendation for management. A GCG study. *Gynecol Oncol* 2006;100:233–8.



- [90] Pruet KM, Gordon AN, Estrada R, Lynch GR. Small-cell carcinoma of the ovary: an aggressive epithelial cancer occurring in young patients. *Gynecol Oncol* 1988;29:365–9.
- [91] Wynn D, Everett GD, Boothby RA. Small cell carcinoma of the ovary with hypercalcemia causes severe pancreatitis and altered mental status. *Gynecol Oncol* 2004;95:716–8.
- [92] Dykgraaf RH, de Jong D, van Veen M, Ewing-Graham PC, Helmerhorst TJ, van der Burg ME. Clinical management of ovarian small-cell carcinoma of the hypercalcemic type: a proposal for conservative surgery in an advanced stage of disease. *Int J Gynecol Cancer* 2009;19:348–53.
- [93] Patsner B, Piver MS, Lele SB, Tsukada Y, Bielak K, Castillo NB. Small cell carcinoma of the ovary: a rapidly lethal tumor occurring in the young. *Gynecol Oncol* 1985;22:233–9.
- [94] Powell JL, McAfee RD, McCoy RC, Shiro BS. Uterine and ovarian conservation in advanced small cell carcinoma of the ovary. *Obstet Gynecol* 1998;91:846–8.
- [95] Liu DM, Kennedy A, Turner D, Rose SC, Kee ST, Whiting S, et al. Minimally invasive techniques in management of hepatic neuroendocrine metastatic disease. *Am J Clin Oncol* 2009;32:200–15.
- [96] Siperstein AE, Rogers SJ, Hansen PD, Gitomirsky A. Laparoscopic thermal ablation of hepatic neuroendocrine tumor metastases. *Surgery* 1997;122:1147–54 discussion 1154–5.
- [97] Gates J, Hartnell GG, Stuart KE, Clouse ME. Chemoembolization of hepatic neoplasms: safety, complications, and when to worry. *Radiographics* 1999;19:399–414.
- [98] Kennedy AS, Dezarn WA, McNeillie P, Coldwell D, Nutting C, Carter D, et al. Radioembolization for unresectable neuroendocrine hepatic metastases using resin 90Y-microspheres: early results in 148 patients. *Am J Clin Oncol* 2008;31:271–9.
- [99] Rhee TK, Lewandowski RJ, Liu DM, Mulcahy MF, Takahashi G, Hansen PD, et al. 90Y Radioembolization for metastatic neuroendocrine liver tumors: preliminary results from a multi-institutional experience. *Ann Surg* 2008;247:1029–35.
- [100] Faiss S, Rath U, Mansmann Uea. Drug therapy in metastatic neuroendocrine tumors of the gastroenteropancreatic system. *Recent Results Cancer Res* 1996;142:193–207.
- [101] Weslin S, Janson E, Sundin A. High-dose treatment with a long-acting somatostatin analogue in patients with advanced midgut carcinoid tumors. *Eur J Endocrinol* 2004;151:107–12.
- [102] Rinke A, Muller HH, Schade-Brittinger C, Klose KJ, Barth P, Wied M, et al. Placebo-controlled, double-blind, prospective, randomized study on the effect of octreotide LAR in the control of tumor growth in patients with metastatic neuroendocrine midgut tumors: a report from the PROMID Study Group. *J Clin Oncol* 2009;27:4656–63.
- [103] Wymenga AN, Eriksson B, Salmela PI, Jacobsen MB, Van Cutsem EJ, Fiasse RH, et al. Efficacy and safety of prolonged-release lanreotide in patients with gastrointestinal neuroendocrine tumors and hormone-related symptoms. *J Clin Oncol* 1999;17:1111.
- [104] Kvols LK, Moertel CG, O'Connell MJ, Schutt AJ, Rubin J, Hahn RG. Treatment of the malignant carcinoid syndrome. Evaluation of a long-acting somatostatin analogue. *N Engl J Med* 1986;315:663–6.
- [105] Janson ET, Oberg K. Long-term management of the carcinoid syndrome. Treatment with octreotide alone and in combination with alpha-interferon. *Acta Oncol* 1993;32:225–9.
- [106] Schnirer II, Yao JC, Ajani JA. Carcinoid—a comprehensive review. *Acta Oncol* 2003;42:672–92.
- [107] Fazio N, de Braud F, Delle Fave G, Oberg K. Interferon-alpha and somatostatin analog in patients with gastroenteropancreatic neuroendocrine carcinoma: single agent or combination? *Ann Oncol* 2007;18:13–9.
- [108] Fjallskog ML, Sundin A, Westlin JE, Oberg K, Janson ET, Eriksson B. Treatment of malignant endocrine pancreatic tumors with a combination of alpha-interferon and somatostatin analogs. *Med Oncol* 2002;19:35–42.
- [109] Yao JC, Phan A, Hoff PM, Chen HX, Charnsangavej C, Yeung SC, et al. Targeting vascular endothelial growth factor in advanced carcinoid tumor: a random assignment phase II study of depot octreotide with bevacizumab and pegylated interferon alpha-2b. *J Clin Oncol* 2008;26:1316–23.
- [110] Phan AT, Yao JC. Neuroendocrine tumors: novel approaches in the age of targeted therapy. *Oncology (Williston Park)* 2008;22:1617–23 discussion 1623–4, 1629.
- [111] Cheng P, Saltz L. Failure to confirm major objective antitumor activity for streptozocin and doxorubicin in the treatment of patients with advanced islet cell carcinoma. *Cancer* 1999;86:944–8.
- [112] Oberg K. Chemotherapy and biotherapy in the treatment of neuroendocrine tumours. *Ann Oncol* 2001;12(Suppl 2):S111–4.
- [113] Sun W, Lipsitz S, Catalano P, Mailliard JA, Haller DG. Phase II/III study of doxorubicin with fluorouracil compared with streptozocin with fluorouracil or dacarbazine in the treatment of advanced carcinoid tumors: Eastern Cooperative Oncology Group Study E1281. *J Clin Oncol* 2005;23:4897–904.
- [114] Hainsworth JD, Spigel DR, Litchy S, Greco FA. Phase II trial of paclitaxel, carboplatin, and etoposide in advanced poorly differentiated neuroendocrine carcinoma: a Minnie Pearl Cancer Research Network Study. *J Clin Oncol* 2006;24:3548–54.
- [115] Kulke MH, Lenz HJ, Meropol NJ, Posey J, Ryan DP, Picus J, et al. Activity of sunitinib in patients with advanced neuroendocrine tumors. *J Clin Oncol* 2008;26:3403–10.
- [116] Duran I, Kortmansky J, Singh D, Hirte H, Kocha W, Goss G, et al. A phase II clinical and pharmacodynamic study of temsirolimus in advanced neuroendocrine carcinomas. *Br J Cancer* 2006;95:1148–54.
- [117] Yao JC, Shah MH, Ito T, Bohas CL, Wolin EM, Van Cutsem E, et al. Everolimus for advanced pancreatic neuroendocrine tumors. *N Engl J Med* 2011;364:514–23.
- [118] Raymond E, Dahan L, Raoul JL, Bang YJ, Borbath I, Lombard-Bohas C, et al. Sunitinib malate for the treatment of pancreatic neuroendocrine tumors. *N Engl J Med* 2011;364:501–13.
- [119] Hobday T, Rubin J, Holen K, Picus J, Donehower R, Marschke R, et al. MC044h, a phase II trial of sorafenib in patients with metastatic neuroendocrine tumors (NET): a Phase II consortium (P2C) study. *J Clin Oncol*. In: *Oncol JC, editor. American Society of Clinical Oncology, vol. 25. J Clinical Oncology; 2007. Orlando, Florida. abstract 4504.*
- [120] Yao JC, Phan AT, Chang DZ, Wolff RA, Hess K, Gupta S, et al. Efficacy of RAD001 (everolimus) and octreotide LAR in advanced low- to intermediate-grade neuroendocrine tumors: results of a phase II study. *J Clin Oncol* 2008;26:4311–8.
- [121] Yao J, Hainsworth E, Baudin M, et al. Everolimus plus octreotide LAR (E + O) versus placebo plus octreotide LAR (P + O) in patients with advanced neuroendocrine tumors (NET): Updated results of a randomized, double-blind, placebo-controlled, multicenter phase III trial (RADIANT-2). *American Society of Clinical Oncology Gastrointestinal Symposium. San Francisco, CA, 29; 2011. (Suppl. 4; abstr 159).*